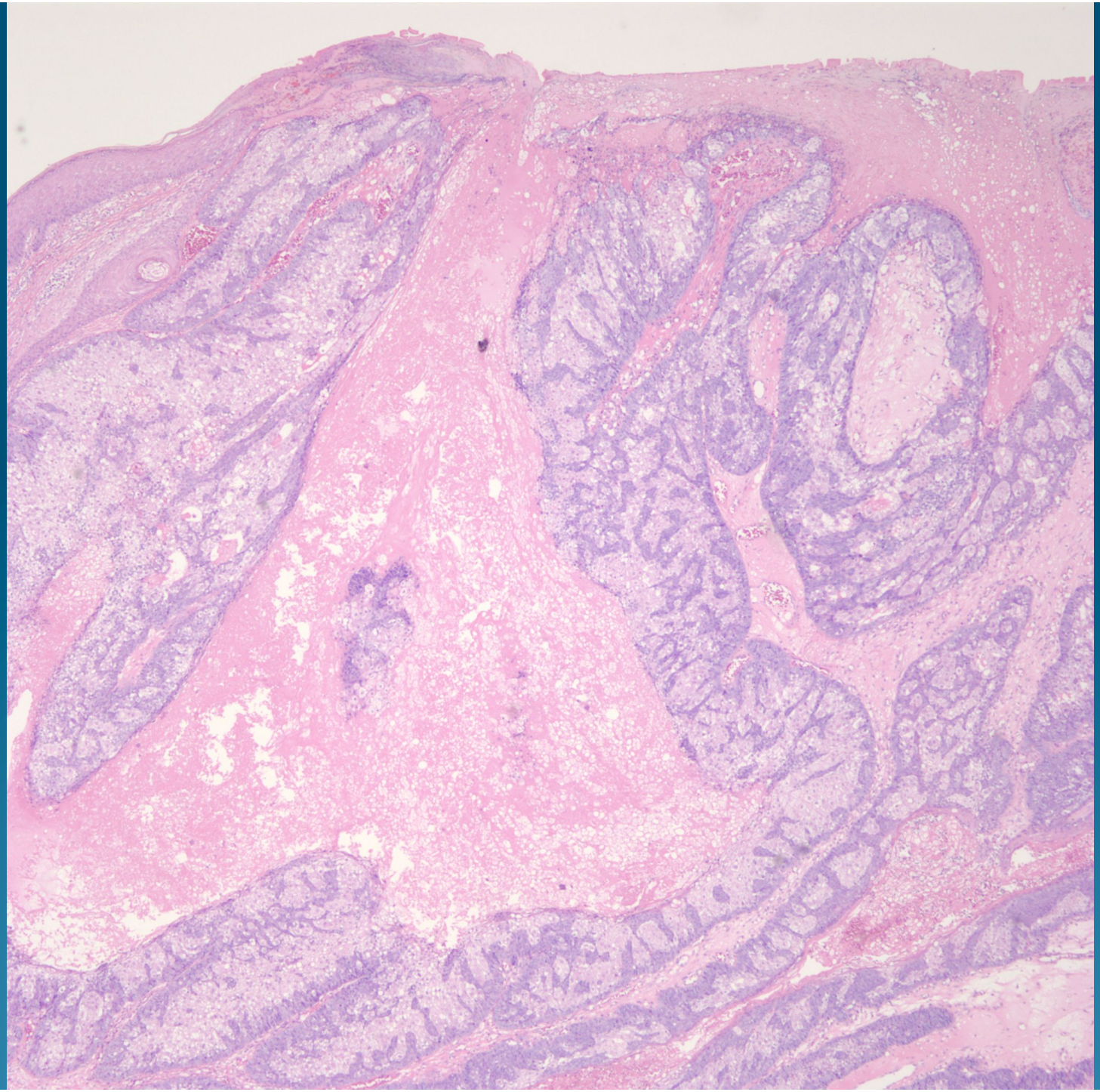

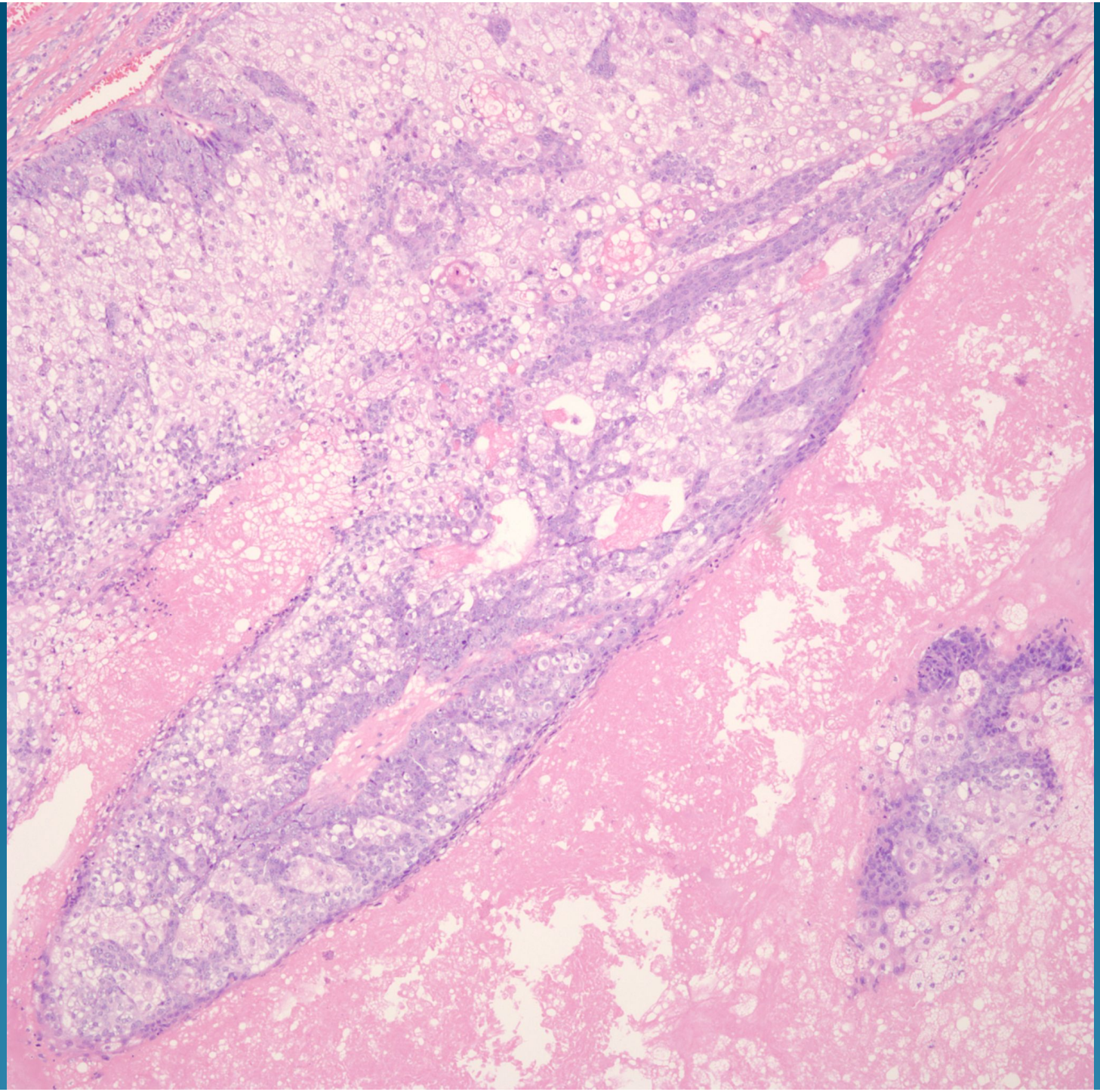

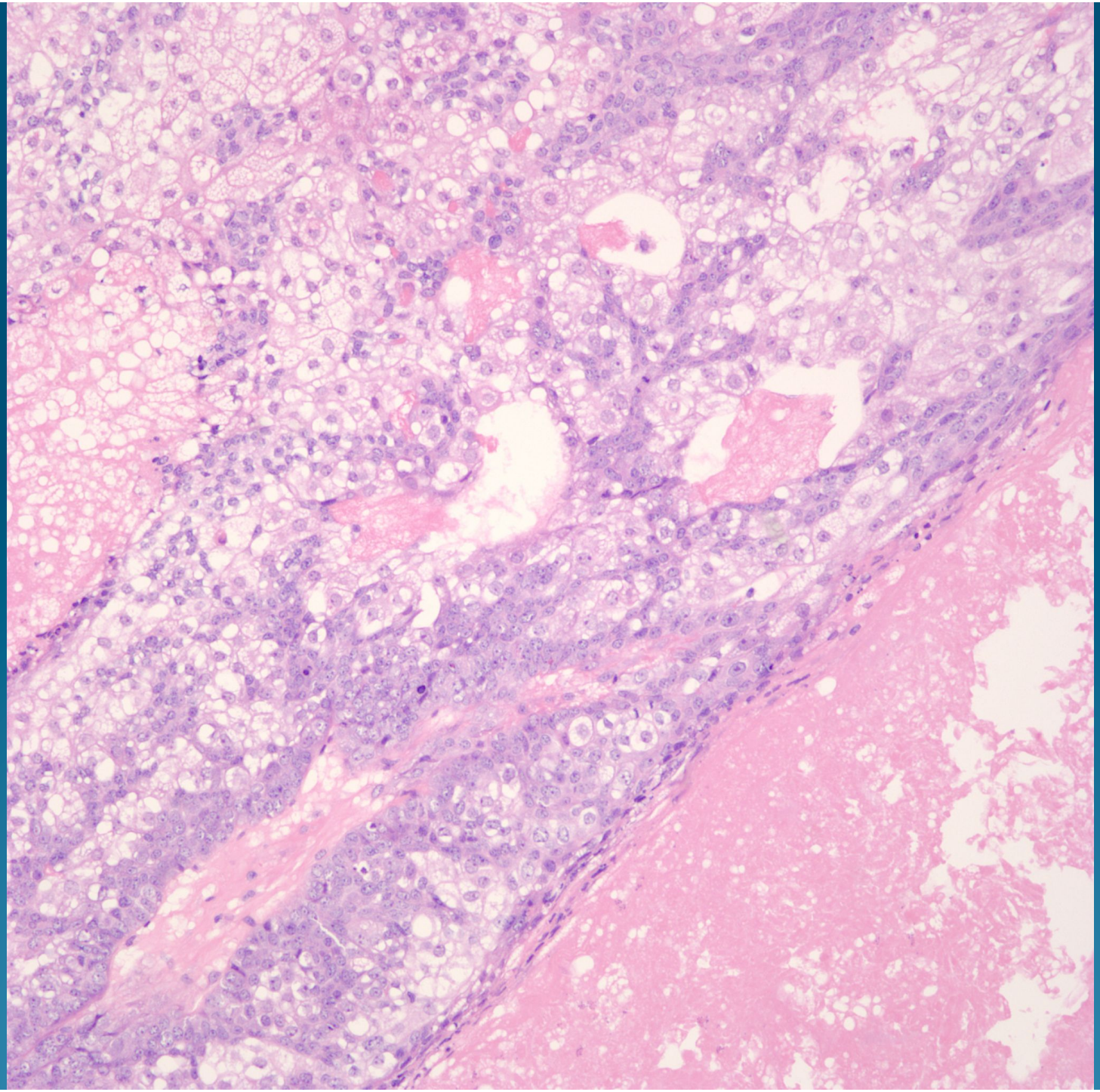

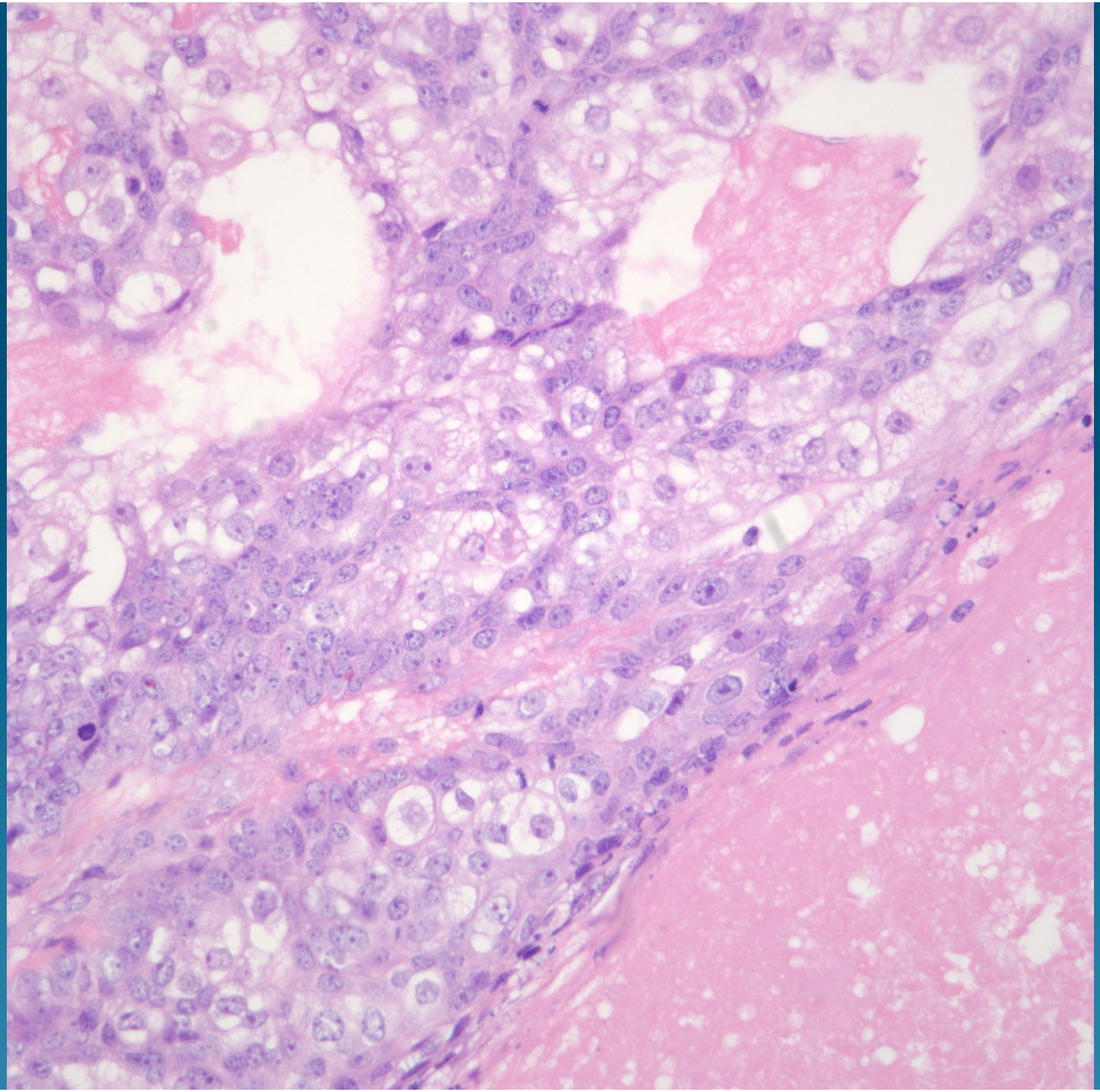

Atypical Sebaceous Tumor in Muir-Torre Syndrome

Pearls

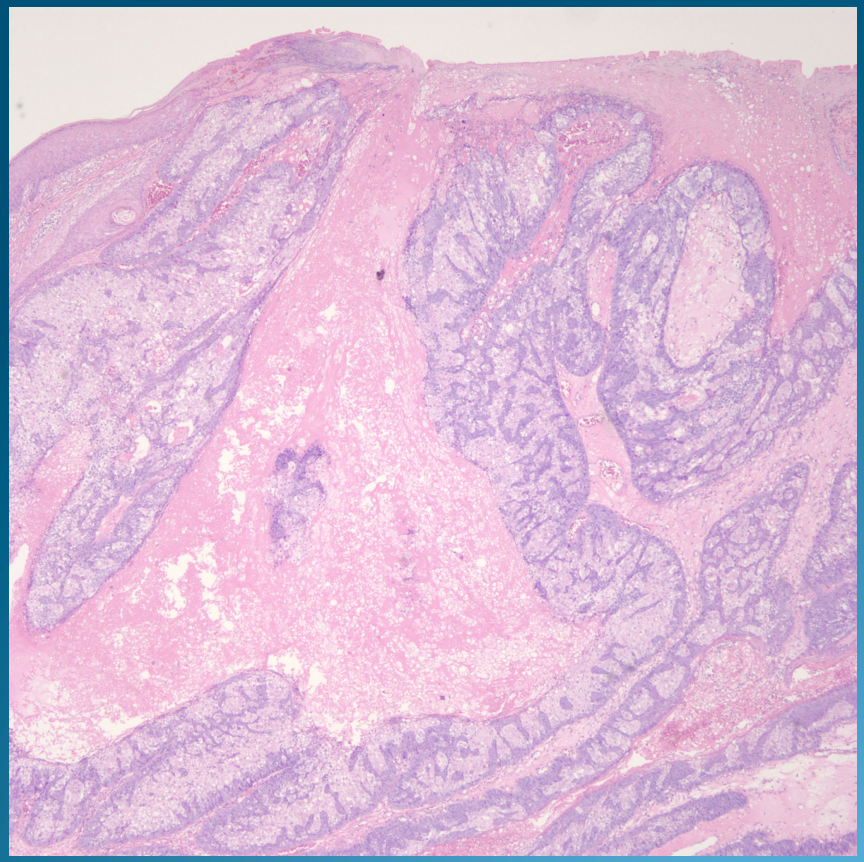

- Nearly all sebaceous neoplasms have been associated with the Muir-Torre syndrome (MTS)
- Clues for MTS include cystic change or verruciform epidermal hyperplasia
- May also confirm by analysis for DNA mismatch repair genes